



## Motor Neuron Disease (MND) Treatment through Acupuncture: My Experience at Suo Xi Hospital in Bangladesh

Dr. S. M. Shahidul Islam<sup>1\*</sup>, Sabina Yasmin<sup>2</sup>, Dr. Huihui Li<sup>4</sup>

<sup>1</sup>Ph.D Fellow in Pain Management, Specially Trained in Acupuncture, Suo Xi Hospital, Shaan Tower, Chamelibagh, Santinagar, Dhaka, Bangladesh

<sup>2</sup>CEO, Shaan Tower, Chamelibagh, Santinagar, Dhaka, Bangladesh

<sup>3</sup>Consultant, Department of Orthopedics and Traumatology, People's Hospital of Chinese Medicine, Ruian City, China

### \*Corresponding Author

**Dr. S. M. Shahidul Islam**

Ph.D Fellow in Pain Management,  
Specially Trained in Acupuncture,  
Suo Xi Hospital, Shaan Tower,  
Chamelibagh, Santinagar, Dhaka,  
Bangladesh

### Article History

Received: 08.03.2022

Accepted: 11.04.2022

Published: 15.06.2022

**Abstract:** Motor neuron disease (MND), often known as amyotrophic lateral sclerosis, is a degenerative neurological illness for which there is no recognized cause (ALS). Increased muscular weakening and bulbar dysfunction lead to respiratory failure, which is the most common cause of mortality [1]. It may be difficult to establish the diagnosis until all of the clinical signs and symptoms are present. One should always get a professional neurology opinion for all types of ailments since there is a wide differential diagnosis to consider, including treatable conditions. Though it is possible that only a small percentage of people with familial ALS can be shown to have an inherited gene disorder, research into the molecular basis of genetic subgroups is yielding vital discoveries that might one day lead to medications for those with sporadic cases [2]. A multidisciplinary team provides supportive care in the absence of a cure or treatment that may alter the course of the illness. Motor neuron illness may be caused by a combination of genetic and environmental factors, and future treatment may involve a combination of molecular medications and stem cell transplantation. A progressive degenerative disease, such as MND or ALS, has no known cause in the patients who suffer from it. When examining the differential diagnosis of motor neuron illnesses, it is necessary to consider the relative involvement of upper and lower motor neurons.

**Keywords:** Motor neuron disease, Electromyography, Electrophoresis, Electromyography, Physiotherapy, Scalp Acupuncture, Tongue Acupuncture, Chinese treatment.

**Copyright © 2022 The Author(s):** This is an open-access article distributed under the terms of the Creative Commons Attribution 4.0 International License (CC BY-NC 4.0) which permits unrestricted use, distribution, and reproduction in any medium for non-commercial use provided the original author and source are credited.

## INTRODUCTION

Primary or secondary muscle weakness may be caused by nerve and motor neurons atrophy or peripheral nerves being damaged, according to neurologists of the seventeenth century. Degeneration of motor neurons has been shown to affect both the upper and lower motor neurons. Charcot and Joffroy used the term "amyotrophic

lateral sclerosis" (ALS) to describe a condition in which both the upper and lower motor neurons are damaged. In the UK, the term "motor neuron disease" (MND) is used more often than "ALS" or "Lou Gehrig's disease" in the US. "Lou Gehrig's disease," or amyotrophic lateral sclerosis (ALS), is an umbrella term in the United States. Diseases like motor neuron disease (MND) often hit people in

**Citation:** S. M. Shahidul Islam, Sabina Yasmin, Huihui Li (2022). Motor Neuron Disease (MND) Treatment through Acupuncture: My Experience at Suo Xi Hospital in Bangladesh. *Glob Acad J Med Sci*; Vol-4, Iss-3 pp- 148-151.

their forties and fifties, with an average diagnosis age of 58. In the United States, motor neuron disease (MND) is the third most common neurodegenerative illness, behind Alzheimer's disease and Parkinson's disease. There has been a lot of discussion concerning physician-assisted suicide and the ethical implications of this disorder because of its harrowing course [3-7]. Motor neuron dysfunctions have been related to a wide range of disorders, both particular and general, originating from a number of neurodegenerative processes. Motor neuron degeneration may occur as a result of toxins and viral infections. There is no known cause for the illness's rapid progression. It is necessary to examine the relative involvement of upper and lower motor neurons while evaluating the various symptoms of a motor neuron disorder.

### CASE REPORT

There is no known cause of Motor Neuron Disease (MND), which proceeds at an unpredictable pace in the bodies of those who suffer from it. The relative involvement of upper and lower motor neurons should be taken into consideration while examining the various symptoms of a motor neuron illness. A 38-year-old male patient came to see us with symptoms of weakness in his left hand and generalized weakness over the last two years, as well as slurred speech. We found nothing noteworthy about his ancestry after digging deep into it. Hypertension was one of his co-morbidities, and he'd had it for four years, during which time he was on high doses of medicine. All four limbs of the patient were subjected to NCS and EMG tests. Electrophysiological testing also revealed the presence of segmental involvement in the cervical

segment, which is in line with a disease of the born cell. CMAP amplitudes of the right median and ulnar nerve's CMAPs were found to be decreasing, but SNAPs seemed normal. An EMG of the muscles in the right upper limb reveals signs of innervation and denervation. Diagnosed with Motor Neuron Disease, a neurological condition. As a result, we planned to use acupuncture on the scalp, acupuncture on the tongue, and acupuncture on the left hand to help the patient heal. In addition, a deep muscle stimulator was used, as did the Chinese approach. After all prior treatments, the patient was given physiotherapy, mobilization, manipulation, and isometric exercise. Acupuncture, deep muscle stimulation, and Chinese medicine all yielded excellent benefits. After the eleventh acupuncture treatment, notable changes started to emerge in the patient. It was found that the weakness and slurred speech were less severe after the eleventh acupuncture session.

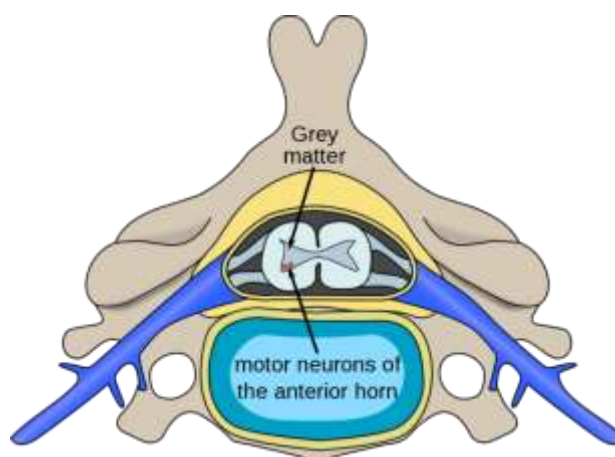
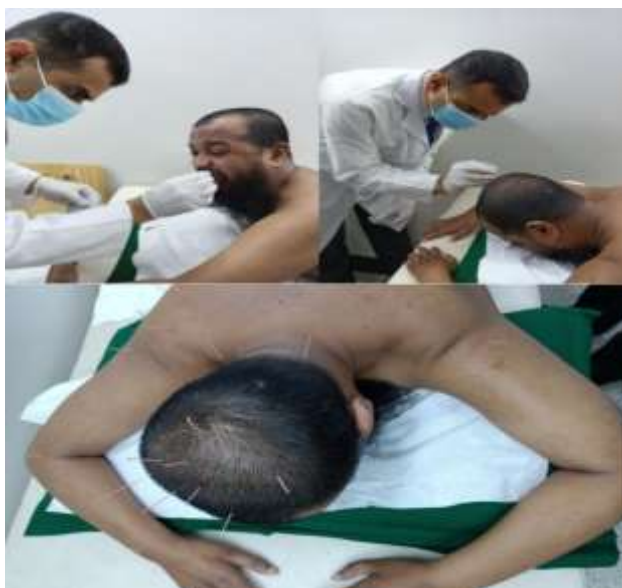

Figure 1: Motor Neuron Disease



Pictures I, II & III: Giving Tongue, Scalp, and Acupuncture at in Left Hand

## DISCUSSION

According to current studies, ALS occurs in the majority of people for unexplained causes. There seems to be minimal variation in the distribution of MND patients, with the exception of physically isolated places like Guam and Guadeloupe, according to published data [8]. Neither an environmental nor a genetic explanation can be drawn from this. Growing diagnostic accuracy, an older population, or a rise in illness frequency are all plausible causes for the apparent rise in incidence during the previous few decades. According to studies, a variety of tropical MNDs (including konzo in Africa and lathyrism in India) have been associated with nutritional factors [9]. For example, pesticides and heavy metals have been linked to a range of ideas but epidemiological evidence for their role in normal sporadic MND remains scarce [10]. In spite of the fact that MND after electrocution may be a legitimate biological illness, this offers nothing to explain why the great majority of instances have been documented. There have also been a lot of studies done on autoimmunity. Autoimmunity to motor neuron disease has not been found to be a viable treatment option for immunomodulation utilizing steroids, intravenous immunoglobulin, or plasma exchange when evaluated in culture [11, 12]. A 38-year-old male patient came to see us with symptoms of weakness in his left hand and generalized weakness over the last two years, as well as slurred speech. We found nothing noteworthy about his ancestry after digging deep into it. Hypertension was one of his co-morbidities, and he'd had it for four years, during which time he was on high doses of medicine. All four limbs of the patient were subjected to NCS and EMG tests. Electrophysiological testing also revealed the presence of segmental involvement in the cervical segment, which is in line with a disease of the born cell. CMAP amplitudes of the right median and ulnar nerve's CMAPs were found to be decreasing, but SNAPs seemed normal. The patient's head, tongue, and left hand would be acupunctured as a consequence. Additional treatment methods included deep muscle stimulators and the Chinese technique. Physiotherapy was offered to the patient after all previous treatments were finished. Chinese medicine, deep muscle stimulation acupuncture, physiotherapy manipulation, and isometric exercise have all shown promising results. After the eleventh acupuncture treatment, there was a noticeable improvement in symptoms. After the eleventh acupuncture session, the slurring of speech became less severe and the left hand's weakness became less pronounced.

## CONCLUSION

At birth or through time, signs of motor neuron disease might begin to manifest in an individual. While some, like ALS, shorten a person's life expectancy, others, like Parkinson's disease, do not; there are currently no approved treatments for most of these ailments. The majority of these illnesses are treated with symptomatic treatment. Using the traditional technique of "scalp, tongue, and muscle" (left hand) acupuncture, the authors have been able to successfully treat muscular weakness and regain the ability to speak clearly again.

## REFERENCES

1. Swash, M. (1992a). Motor neuron disease. *Postgraduate Medical Journal*, 68(801), 533-537. <https://doi.org/10.1136/pgmj.68.801.533>
2. Lyall, R. A., Donaldson, N., Fleming, T., Wood, C., Newsom-Davis, I., Polkey, M. I., Leigh, P. N., & Moxham, J. (2001a). A prospective study of quality of life in ALS patients treated with noninvasive ventilation. *Neurology*, 57(1), 153-156. <https://doi.org/10.1212/wnl.57.1.153>
3. Kuzuhara, S., Kokubo, Y., Sasaki, R., Narita, Y., Yabana, T., Hasegawa, M., & Iwatsubo, T. (2001). Familial amyotrophic lateral sclerosis and parkinsonism-dementia complex of the Kii Peninsula of Japan: clinical and neuropathological study and tau analysis. *Annals of Neurology*, 49(4), 501-511. <https://doi.org/10.1002/ana.100>
4. Charcot, J., & Joffroy, A. (n.d.-a). *Deux cas d'atrophie musculaire progressive avec lesions de la substance grise et des faisceaux antero-lateraux de la moelle epiniere*. Retrieved January 11, 2022, from <https://www.semanticscholar.org/paper/1bd576ce0b241d25add7bd193c8b71adda93cf22>
5. Ringel, S. P., Murphy, J. R., Alderson, M. K., Bryan, W., England, J. D., Miller, R. G., Petajan, J. H., Smith, S. A., Roelofs, R. I., & Ziter, F. (1993). The natural history of amyotrophic lateral sclerosis. *Neurology*, 43(7), 1316-1322. <https://doi.org/10.1212/wnl.43.7.1316>
6. Traynor, B. J., Codd, M. B., Corr, B., Forde, C., Frost, E., & Hardiman, O. (1999b). Incidence and prevalence of ALS in Ireland, 1995-1997: a population-based study. *Neurology*, 52(3), 504-509. <https://doi.org/10.1212/wnl.52.3.504>
7. Piemonte and Valle d'Aosta Register for Amyotrophic Lateral Sclerosis (PARALS). (2001a). Incidence of ALS in Italy: evidence for a uniform frequency in Western countries. *Neurology*, 56(2), 239-244. <https://doi.org/10.1212/wnl.56.2.239>

8. Ludolph, A. C., & Spencer, P. S. (1996). Toxic models of upper motor neuron disease. *Journal of the Neurological Sciences*, *139 Suppl*, 53–59. [https://doi.org/10.1016/0022-510x\(96\)00122-0](https://doi.org/10.1016/0022-510x(96)00122-0)
9. Howlett, W. P., Brubaker, G. R., Mlingi, N., & Rosling, H. (1990a). Konzo, an epidemic upper motor neuron disease studied in Tanzania. *Brain: A Journal of Neurology*, *113*(1), 223–235. <https://doi.org/10.1093/brain/113.1.223>
10. Jafari, H., Couratier, P., & Camu, W. (2001). Motor neuron disease after electric injury. *Journal of Neurology, Neurosurgery, and Psychiatry*, *71*(2), 265–267. <https://doi.org/10.1136/jnnp.71.2.265>
11. Meucci, N., Nobile-Orazio, E., & Scarlato, G. (1996). Intravenous immunoglobulin therapy in amyotrophic lateral sclerosis. *Journal of Neurology*, *243*(2), 117–120. <https://doi.org/10.1007/bf02444000>
12. Rowland, L. P. (1991c). Ten central themes in a decade of ALS research. *Advances in Neurology*, *56*, 3–23. <https://pubmed.ncbi.nlm.nih.gov/1853764/>